



PATIENT

Ms. Silky Schneider

SPECIES

Feline

DSH

SEX

FS

AGE

14 years

WEIGHT

3.9 kg

INTERPRETED BY

Remo Lobetti, BVSc,
MMedVet (Med),
PhD, Dipl. ECVIM

**IMAGING
PERFORMED BY**

Brent Crutchfield,
DVM

HOSPITAL NAME

Treasure Coast
Animal Emergency

REFERRING VET

Angela Cail

INVOICE

303603

DATE

11/28/22

PRESENTING CLINICAL SIGNS

History: UTI and chronic kidney disease.

Physical Examination: N/A.

Urinalysis: N/A

CBC: N/A.

Serum Biochemistry: N/A.

Radiographic Findings: N/A.

ULTRASONOGRAPHIC EXAMINATION OF THE ABDOMEN

Urinary System

Full urinary bladder with a normal thickness (0.1 cm) and appearance of the wall. Normal anechoic urine with no sediment or uroliths evident.

Normal trigone area, proximal urethra, and iliac blood vessels.

Normal iliac lymph nodes (0.7 cm). Ureters not visualized.

Normal renal size (left kidney 3.1 cm, right 3.2 cm) with increased echogenic appearance, some loss of cortico-medullary differentiation, normal capsule, and bilateral pyelectasia.

Reproductive System

N/A.

Adrenal Glands

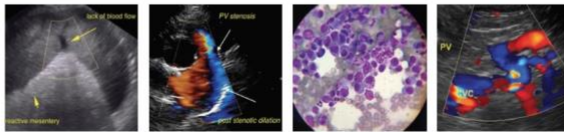
Normal position, echogenic appearance, shape, and size. Right 0.33 cm.

Spleen

Enlarged (1.1 cm) with a mottled echogenic appearance. Smooth homogenous parenchyma, regular curvilinear capsule, and normal vasculature. No evidence of inflammatory, neoplastic, infarction, or infiltrative changes noted.

Liver

Normal size, echogenic appearance, portal markings, and regular curvilinear capsule. No nodules or masses evident. Full gall bladder containing normal anechoic bile. Normal thickness (0.1 cm) and echogenic appearance of the gall bladder wall. Normal bile duct.



PATIENT

Ms. Silky Schneider

SPECIES

Feline

DSH

SEX

FS

AGE

14 years

WEIGHT

3.9 kg

INTERPRETED BY

Remo Lobetti, BVSc,
MMedVet (Med),
PhD, Dipl. ECVIM

IMAGING PERFORMED BY

Brent Crutchfield,
DVM

HOSPITAL NAME

Treasure Coast
Animal Emergency

REFERRING VET

Angela Cail

INVOICE

303603

DATE

11/28/22

Gastrointestinal

Normal appearance of the gastro-esophageal junction, stomach, duodenum, small intestine, ileo-cecal junction, and colon with no loss of layering, normal wall thickness (stomach 0.21 cm, duodenum 0.24 cm, jejunum 0.22 cm, colon 0.14 cm) and peristaltic activity, and no distension of the lumen.

Pancreas

Normal size and echogenic appearance. Regular capsule. Normal echogenic appearance of the mesentery and fat surrounding the pancreas.

Free Abdomen

No mesenteric lymphadenomegaly.
No ascites.

ULTRASONOGRAPHIC FINDINGS

Primary findings:

- Splenomegaly.
- Renal disease.

Secondary findings:

- None.

INTERPRETATION OF THE FINDINGS & FURTHER RECOMMENDATIONS IMAGES

Etiologies for the splenomegaly would be reactive, hyperplasia, and infiltrative neoplasia (mast cell, lymphoma).

Etiologies for the renal disease would be chronic kidney disease, bacterial nephritis, and pyelonephritis.

Further assessment would urine analysis, urine culture, UPC (if culture and sediment negative), renal function (urea, creatinine, SDMA), blood pressure, and FNA cytology of the spleen.

Specific therapy would be dependent on an etiological diagnosis.



PATIENT

Ms. Silky Schneider

SPECIES

Feline

DSH

SEX

FS

AGE

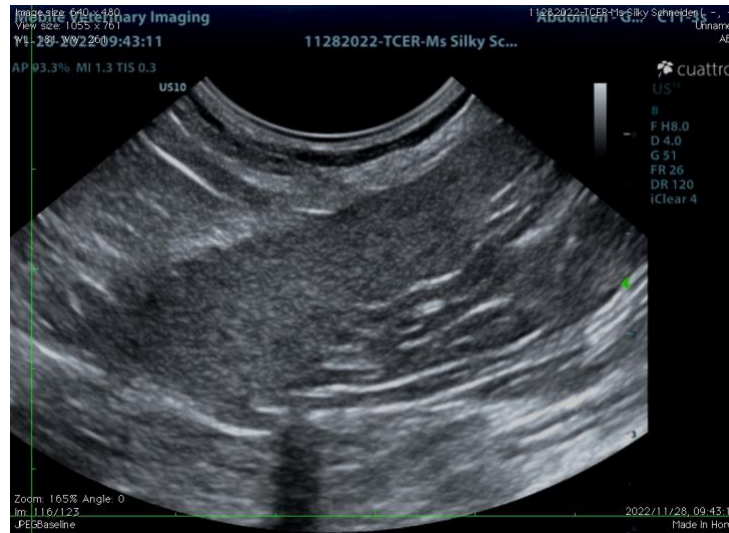14 years

WEIGHT

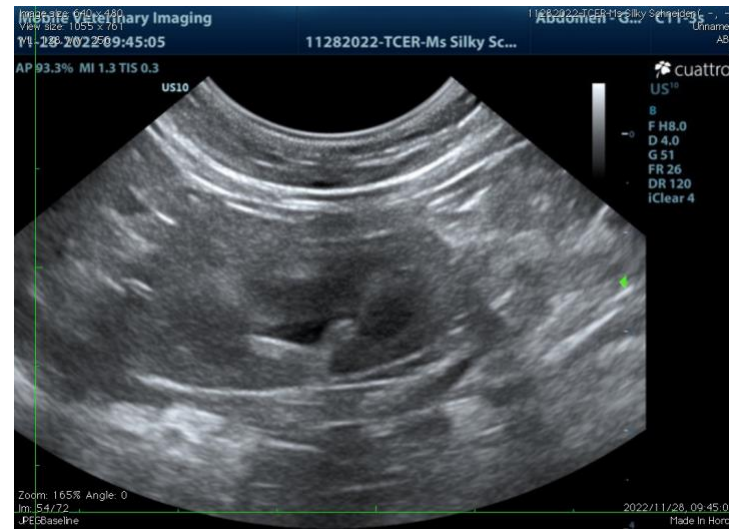3.9 kg

IMAGES

Spleen



Right kidney



INTERPRETED BY

Remo Lobetti, BVSc,
MMedVet (Med),
PhD, Dipl. ECVIM

IMAGING PERFORMED BY

Brent Crutchfield,
DVM

HOSPITAL NAME

Treasure Coast
Animal Emergency

REFERRING VET

Angela Cail

INVOICE

303603

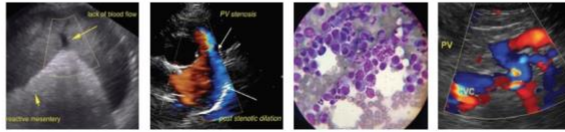
DATE

11/28/22

The information and recommendations provided are based on the images presented by the referring veterinarian. No evaluation can be communicated regarding pathology that was not visible in the image/video clips provided.

Thank you for this referral. If the clinical or image interpretation does not parallel your findings or if I can be of any further assistance please contact me.

Remo Lobetti, BVSc, MMedVet (Med), PhD, Dipl. ECVIM (Internal Medicine)
rlobetti@mweb.co.za



PATIENT

Ms. Silky Schneider

SPECIES

Feline

DSH

SEX

FS

AGE

14 years

WEIGHT

3.9 kg

INTERPRETED BY

Remo Lobetti, BVSc,
MMedVet (Med),
PhD, Dipl. ECVIM

**IMAGING
PERFORMED BY**

Brent Crutchfield,
DVM

HOSPITAL NAME

Treasure Coast
Animal Emergency

REFERRING VET

Angela Cail

INVOICE

303603

DATE

11/28/22